

12-3-2019

## DIAGNOSIS AND TREATMENT METHOD OF IMPACTED TEETH ON THE UPPER JAW

Mikhail A. Postnikov

*Federal State Budgetary Educational Institution of Higher Education "Samara State Medical University" of the Ministry of Health of the Russian Federation Chapaevskaya St. 89, Samara, Russian Federation, 443099, postnikovortho@yandex.ru*

Dmitriy A. Trunin

*IPE Samara State Medical University, Director of the Dental Institute of the Samara State Medical University, President of the StAR, Chief External Expert-Dentist*

Maksim M. Kirilin

*Orthodontist, Center for Integrated Dentistry, LLC*

Grigoriy V. Stepanov

*Federal State Budgetary Educational Institution of Higher Education "Samara State Medical University" of the Ministry of Health of the Russian Federation Chapaevskaya St. 89, Samara, Russian Federation, 443099*

Follow this and additional works at: <https://uzjournals.edu.uz/tma>

---

### Recommended Citation

Postnikov, Mikhail A.; Trunin, Dmitriy A.; Kirilin, Maksim M.; and Stepanov, Grigoriy V. (2019) "DIAGNOSIS AND TREATMENT METHOD OF IMPACTED TEETH ON THE UPPER JAW," *Central Asian Journal of Medicine*: Vol. 2019 : Iss. 4 , Article 12.

Available at: <https://uzjournals.edu.uz/tma/vol2019/iss4/12>

This Article is brought to you for free and open access by 2030 Uzbekistan Research Online. It has been accepted for inclusion in Central Asian Journal of Medicine by an authorized editor of 2030 Uzbekistan Research Online. For more information, please contact [sh.erkinov@edu.uz](mailto:sh.erkinov@edu.uz).

## DIAGNOSIS AND TREATMENT METHOD OF IMPACTED TEETH ON THE UPPER JAW

Mikhail A. Postnikov<sup>1</sup>, Dmitriy A. Trunin<sup>2</sup>, Maksim M. Kirilin<sup>3</sup>,  
Grigoriy V. Stepanov<sup>4</sup>, Mariya S. Chistyakova<sup>5</sup>

**Federal State Budgetary Educational Institution of Higher Education "Samara State Medical University" of the Ministry of Health of the Russian Federation  
Chapaevskaya St. 89, Samara, Russian Federation, 443099**

*1* MD, Associate Professor of the Department of Dentistry, IPE Samara State Medical University, Advisor to the President of the StAR, StAS Vice President, Orthodontist of the highest category, Director of the Postnikov Multidisciplinary Clinic. Cont. : + 7-960-830-00-06, [postnikovortho@yandex.ru](mailto:postnikovortho@yandex.ru)

*2* MD, Professor, Head of the Department of Dentistry, IPE Samara State Medical University, Director of the Dental Institute of the Samara State Medical University, President of the StAR, Chief External Expert-Dentist

*3* Orthodontist, Center for Integrated Dentistry, LLC

*4* MD, Professor, Head of the Department of Pediatric Dentistry, Samara State Medical University

*5* Prosthodontist

### ABSTRACT

**Research objective:** To increase the efficacy of diagnosis and comprehensive treatment of patients with impacted incisors and canines on the maxilla; to develop and propose a new technique for determining the topography of impacted teeth (incisors and canines) on the maxilla, using the highly informative data of cone-beam computed tomography; to apply a new method of diagnosis in the planning of comprehensive orthodontic treatment of patients with impacted teeth; to introduce this method into the clinical practice of orthodontist.

**Materials and methods.** In the process of the research to obtain a three-dimensional image the X-ray device "PlanmecaProMax 3D Mid" with «Planmeca Romexis» – the software

for saving, viewing and changing images were applied. For composing and conducting measurements on the image we used "Dolphin Imaging" (3D Surgery and Ceph Tracing) (USA) program. In determination of the levels of impacted teeth location and angles of their longitudinal axes inclination in three mutually perpendicular planes according to the proposed technique we applied a computed tomogram of patient.

**Findings.** Using the data of cone-beam computed tomography, the orthodontist developed and introduced into practice a method for determining the spatial location of frontally impacted teeth in the upper jaw. This method allows to determine the level of location and the degree of its inclination, which is very important when planning complex orthodontic and surgical treatment of patients with impacted teeth.

**Key words:** impacted teeth, diagnosis, orthopantomography, cone-beam computed tomography, comprehensive orthodontic treatment.

## INTRODUCTION

Diagnosis and treatment of patients with impaction of permanent teeth is one of the urgent problems of modern dentistry due to morphological, functional and aesthetic changes that occur in case of absence of a tooth in the dentition, which leads to violation of the social adaptation of the individual.

Today, tooth impaction is a fairly common anomaly of the maxillofacial system: for 100 children seeking orthodontic care, 15-20 have malocclusion complicated by the impaction of one or more teeth (Budkova T.S., Zhigurt Yu.I., Khoroshilkina F.I., 1997). The front teeth of the upper jaw are more often impacted: central incisors and canines - 61.6% (Stepanov G.V., 2008).

Classic cases of treatment of patients with impacted teeth require traditional orthodontic treatment. [1]. However, in cases where the impacted tooth has an anomaly of location, incorrect inclination or unfavorable individual anatomical features, then a combined surgical and orthodontic treatment is certainly assumed [2]. Therefore, in such cases, it is especially important to determine the exact location of the retention tooth.

When teething is delayed, X-ray examination methods are fundamental both in the diagnosis and in the treatment planning.

There are some methods of determining the location levels of impacted anterior teeth. The most common and generally accepted is the method proposed by Yu. I. Zhigurt (1994). The study of the location of the impacted teeth is carried out using an orthopantomogram of the jaw, where 4 levels of the location of the impacted incisors of the upper jaw and canines are determined. On the orthopantomogram, a median line is drawn, which coincides with the median plane. Then 2 horizontal lines are drawn, perpendicular to the median plane: one

through the point of extension, the second through the point of the anterior nasal spine. The vertical distance between these lines is divided into 4 equal parts and horizontal lines are drawn through the obtained points. The first level of the tooth is located between the two lower lines, the fourth - between the two upper lines, the second and third - in the middle [3].

Method of Yu.I. Zhigurt can also be used to measure the angle of inclination of the impacted teeth: the mid-sagittal plane is drawn on the orthopantomogram through the middle of the vomer and the anterior nasal spine. Then a horizontal plane is drawn perpendicularly to level of incisal surface of the permanent central incisors of the upper jaw. Angles of inclination of the longitudinal axes of impacted teeth located in the anterior part of the dentition (upper internal angles) are determined relative to this plane. Three degrees of inclination of the longitudinal axes of the impacted teeth were determined: I degree - up to 105 °, II degree - 105-120 °, III degree - more than 120 °.

Despite its widespread use among orthodontists, this method has a number of significant disadvantages. It is impossible to reliably determine the position and placement of elements of the upper and lower jaw on an orthopantomogram, including teeth, since the anatomical structures are deformed due to their overlap. It was also found that the true vertical and horizontal linear dimensions of the teeth and jaws are significantly distorted on the orthopantomogram. As a result, it becomes impossible to determine the overall magnification of the image. In addition, on the orthopantomogram, a cut is made at a certain depth, so the image of impacted teeth located not in the center of the alveolar bone can be either enlarged or reduced (Khoroshilkina F.Ya., 2006). The foregoing indicates that this method is not informative enough and does not allow to accurately assess the location of the impacted tooth on the jaw.

### **RESEARCH OBJECTIVE**

To increase the efficacy of diagnostics and comprehensive treatment of patients with impacted teeth by creating a new method of determining the location of impacted maxillary incisors and canines, using cone beam computed tomography.

### **MATERIALS AND METHODS**

The development of the method of diagnosis and comprehensive treatment of patients with impacted maxillary incisors and canines was carried out at the Department of Postgraduate Dentistry of Samara State Medical University. During the research we studied and analyzed data of 12 computed tomograms of 6 patients with impacted maxillary teeth. Each patient underwent 2 three-dimensional images, one of which was used to study the level of location, and the second to determine the angle of inclination of the longitudinal axis of the tooth.

We used X-ray device «Planmeca ProMax 3DMid» for cone-beam computed tomography, as well as computer graphics software «Planmeca Romexis» to work with the x-ray

images. After performing a CBCT in the area of the impacted tooth, an X-ray image was obtained in three planes: coronary - left upper corner, axial - left lower corner, sagittal - right upper corner, and volumetric image - right lower corner, which allowed to determine the current orientation X, Y and Z planes and current image scale. A rectangular coordinate system was displayed in the window of each slice, with the help of which the parameters of the impacted tooth and its location in the jaw were measured.

Besides, we used the 3D module of the Dolphin Imaging computer program (USA) to determine the level of location of the impacted teeth and to take measurements on the obtained image.

The method proposes determination of the location of levels of the impacted maxillary frontal teeth (incisors, canines) with using of cone beam computed tomography. Two horizontal lines are drawn on the computed tomography of the patient: one through the points Spina nasalis anterior (Sna) and Spina nasalis posterior (Snp), and the other through the apical base of the upper jaw. The vertical distance between these lines is divided into three equal parts and horizontal lines are drawn through the resulting points. The first level of the tooth is located between the two lower lines, the third - between the two upper lines, the second - in the middle (Fig. 1).

To determine the level of location of the impacted tooth on the CBCT, an image in the sagittal plane was used. It was found that it is advisable to distinguish precisely three levels of location of the impacted tooth, since the vertical distances between the horizontal lines correspond to the size of crown of the impacted tooth. We determine the level of location of the impacted tooth by the zone, where tooth's crown is.

There is a rectangular coordinate system in the window of each plane on the CBCT. The axes of this system were used by us to measure the angles of inclination of the impacted teeth axes.

To measure the axis of inclination of the impacted tooth, we measured the angle, one side of which was the middle axis of the impacted tooth, and the other side was a line drawn parallel to the horizontal axis of the rectangular coordinate system in the sagittal plane and parallel to the vertical axis of the coordinate system – in coronary and axial planes. The angle was determined with an accuracy of  $0.01^\circ$ .

According to our method, three degrees of inclination of the impacted tooth axes were determined by computed tomogram in each of the planes (*Table 1*).

**Table 1.**

**Determination of the degree of inclination of the impacted teeth axes (incisors, canines of the upper jaw) in three planes according to cone beam computed tomography.**

Plane	Degree	Angle value
Coronary	1	up to 45 °
	2	45 ° - 90 °
	3	more than 90 °
Sagittal	1	up to 100 °
	2	100 ° - 120 °
	3	more than 120 °
Axial	1	up to 45 °
	2	45 ° – 90 °
	3	more than 90 °

## RESULTS AND DISCUSSION

During the research we performed 12 computed tomograms for 6 patients with impacted maxillary teeth in the frontal part (incisors, canines) before treatment and found 6 impacted teeth (2 central incisors, 1 lateral incisor, 3 canines) located at different levels. First level of location was detected in 1 patient (16.7%), second level – in 2 patients (33.3%), third level – in 3 patients (50%). We obtained the following data (Table 2) when determining the degrees of inclination of the impacted teeth axes in three planes [4].

**Table 2.**

**The degrees of inclination of the impacted teeth axes according to cone beam computed tomography.**

Patient	Plane					
	Coronary	Degree	Sagittal	Degree	Axial	Degree
1	36,87°	1	118,72°	2	37,72°	1
2	12,51°	1	105,39°	2	29,85°	1
3	34,20°	1	136,45°	3	33,76°	1
4	22,78°	1	175,25°	3	18,46°	1
5	29,48°	1	141,09°	3	29,75°	1
6	56,33°	2	129,88°	3	57,93°	2

In 5 patients (83.3%) with I degree of violation of the angle of inclination of the impacted tooth longitudinal was detected in the coronary and axial planes; II degree – in the coronary and axial planes in 1 patient (16.7%), in the sagittal plane – 2 patients (33.3%); III degree disorders were detected only in the sagittal plane in 4 patients (66.7%).

In application of this method in clinical practice the following was found out: the closer the impacted tooth was located to the spinal plane and the more parallel plane of axis of the impacted tooth to the spinal plane (Spina nasalis anterior (Sna) and Spina nasalis posterior (Snp)), the less favorable were treatment outcomes. In addition, the greater was the angle of inclination of the impacted tooth to the spinal plane, the worse was the prognosis of treatment. Thus, when the impacted tooth is located at the 1st level of location, the time of comprehensive treatment will be 16-18 months. When the tooth is located at the 2<sup>nd</sup> level – it will take 18-24 months; at the 3<sup>rd</sup> level – 24-32 months [5,6].

### Clinical case

Patient O., 13 years old, complained about absence of an upper central incisor in the dental arch, vestibular position of an upper canine on the left, and crowding of teeth on the upper and lower jaws. Clinical examination was carried out according to standard methods. Examination of the oral cavity revealed the absence of tooth 1.1 (Fig. 2).

An X-ray examination of the patient included orthopantomography, telereöntgenography of head in lateral projection, using Dolphin Imaging software to analyze cephalometric radiographs and cone beam computed tomography of the tooth 1.1. The study of orthopantomogram was carried out according to the method of Yu.I. Zhigurt. The location level of the impacted tooth 1.1 was determined, as well as the angle of inclination of its longitudinal axis (Fig. 3). We noted three levels of the impacted teeth location in the sagittal plane on CT scan of the upper jaw according to our method. The 3<sup>rd</sup> level of the impacted tooth 1.1 location was determined (Fig. 4).

Then, we measured angles of inclination of the impacted tooth 1.1 in three mutually perpendicular planes (Fig. 5).

As a result of measurements, we obtained the following angles: in the coronary plane - 56.33 °, in the sagittal plane - 129.88 °, in the axial plane - 57.93 °. Then, we compared the obtained data with the data in Table 1. Angle of inclination of the impacted tooth 1.1: in the coronary plane - II degree; in the sagittal plane - III degree; in the axial plane - II degree.

Considering the obtained data, we made the diagnosis: malocclusion class II, impaction and transposition of the tooth 1.1, crowding of teeth on the upper and lower jaws of II-III degrees, vestibular position of the tooth 2.3.

Patient underwent comprehensive surgical and orthodontic treatment. We made one more cephalometric x-ray at the stage of orthodontic treatment with its analysis in Dolphin Imaging (Fig. 6). X-ray examination was performed again after the orthodontic treatment (Fig. 7, 8). Comprehensive treatment of patient O. lasted 2 years and 5 months.

## CONCLUSION

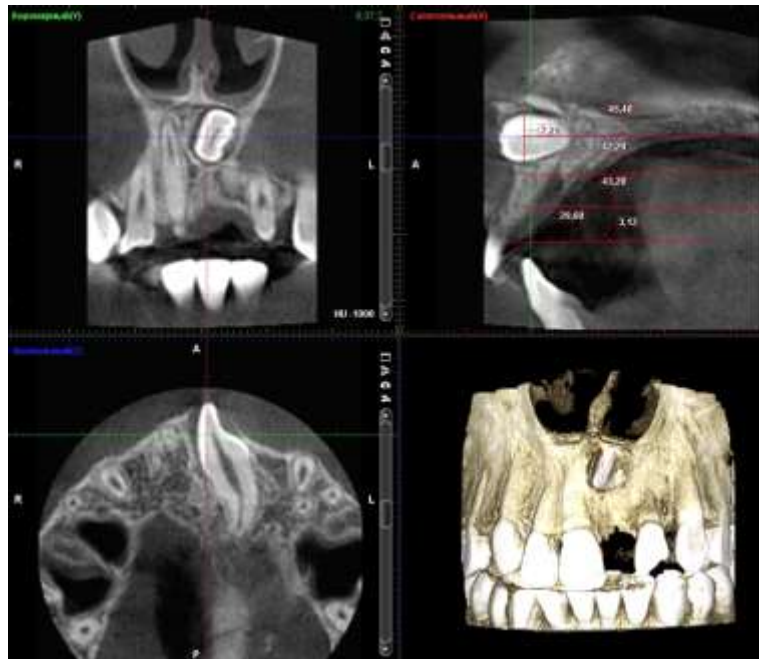
We have developed a method for determining the location of impacted teeth (incisors, canines) of the upper jaw using data of cone beam computed tomography (registration number of patent of the Russian Federation No. 2017136914 dated 10.19.2017). The given image allows us to analyze the state of elements of upper jaw from all sides without distortion. Therefore, it allows us to determine the level of impacted tooth location, the angle of inclination of its longitudinal axis more accurately.

The diagnosis of impacted upper canines and incisors is insufficient only by the orthopantomogram of the jaw. The new diagnostic method allows planning complex treatment. Orthodontists can use this method to more accurately determine the degree of position of the impacted tooth, the direction of elastic traction in accordance with the measured angles of inclination of the impacted tooth, and to calculate the approximate duration of treatment.

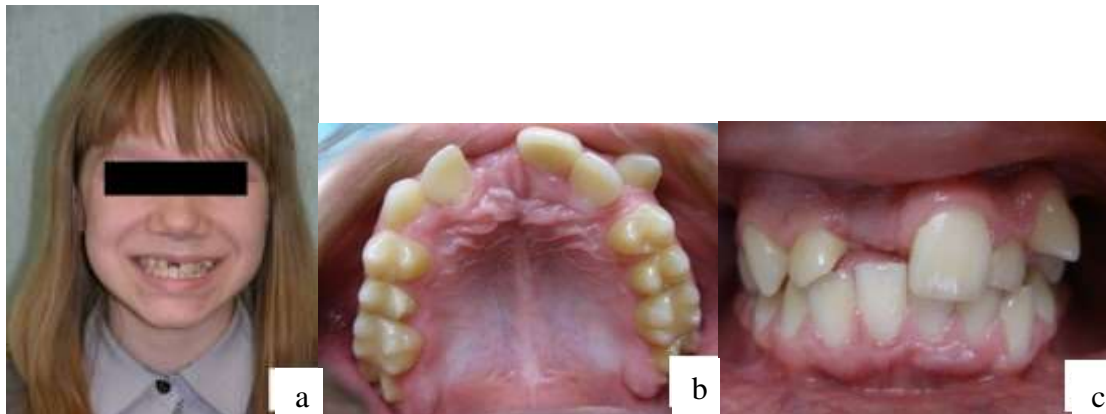
## REFERENCES

1. Arsenina O.I., Proskokova S.V., Sapezhnikova S.A. Modern methods of examination of patients with impacted teeth. *Ortodontiya*. – 2010. - №1.
2. Vakushina E.A., Bragin E.A. Using computed tomography in diagnostics and treatment of impacted teeth. *Ortodontiya*. Moscow. – 2004. - №2.
3. Postnikov M.A. Perfection of methods of orthodontic treatment of patients with impacted teeth. *Stomatologiya detskogo vozrasta i profilaktika*. – 2009. - 6(2). 30-36 p.
4. Postnikov M.A., Stepanov G.V., Seregin A.S., Kirilin M.M., Ulyanova L.G. Perfection of methods of diagnosis and treatment of patients with impacted teeth. *Stomatologiya detskogo vozrasta I profilaktika*. – 2017. – 16.2(61). – 28-31 p.
5. Aydin U., Yilmaz H. H., Yildirim D. Incidence of canine impaction and transmigraton in a patient population//Department of Oral Diagnosis and Radiology, School of Dentistry, SuleymanDemirel University, Isparta, Turkey. 2004.
6. Chaushu S., Becker A., Zeltser R., Vasker N., Chaushu G. Patients perceptions of recovery after surgical exposure of impacted maxillary teeth treated with an open-eruption surgicalorthodontic technique//*European Journal of Orthodontics*. 2004. T. 26. №6.

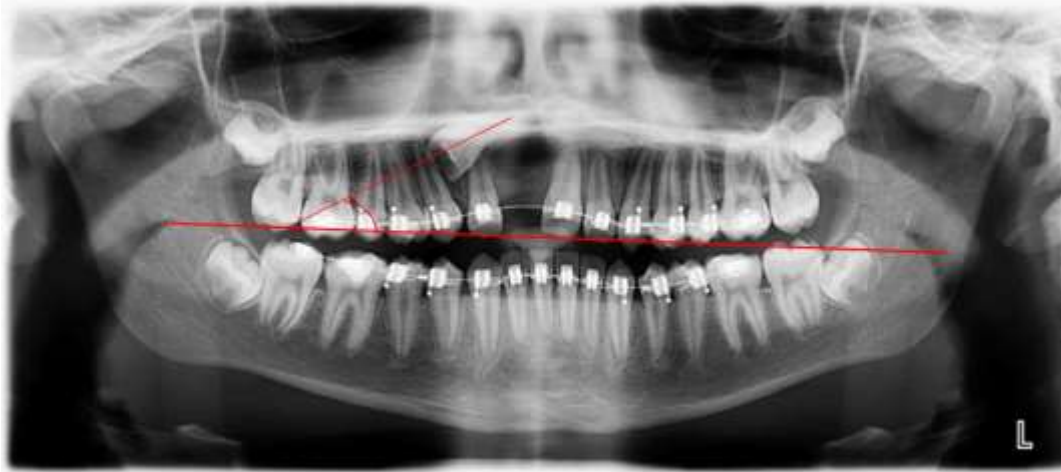




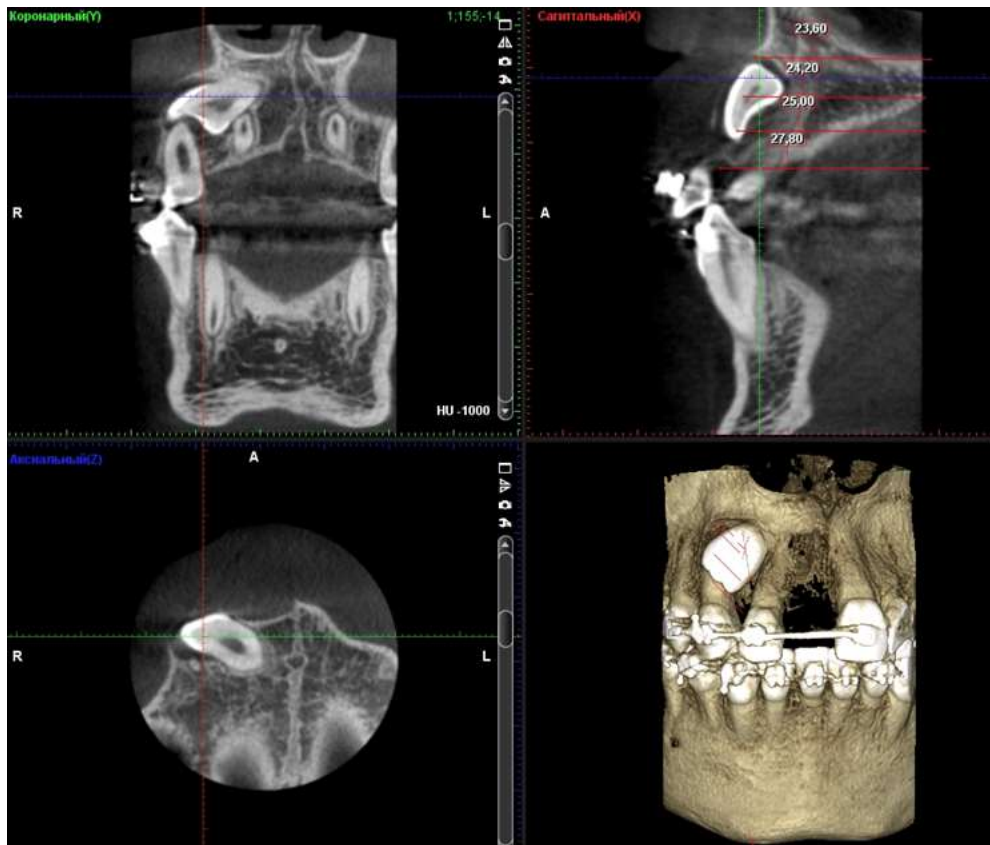
**Fig.1. Determination of three levels of the impacted teeth location (incisors and canines of the upper jaw) on the CBCT of patient A., 14 years old (III level of tooth 2.1 location)**



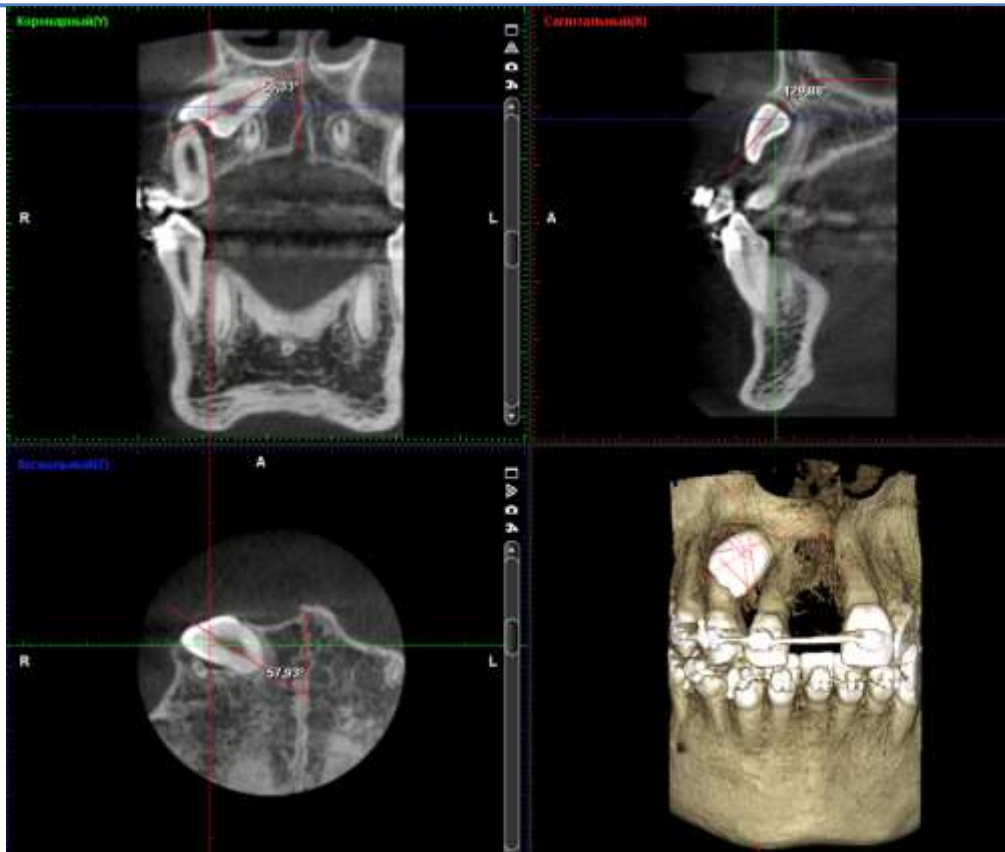
**Fig.2. Photo of patient O., 13 years old with impacted tooth 1.1 before orthodontic treatment: patient's face (a), upper dentition from (b), closure of dentition front view (c).**



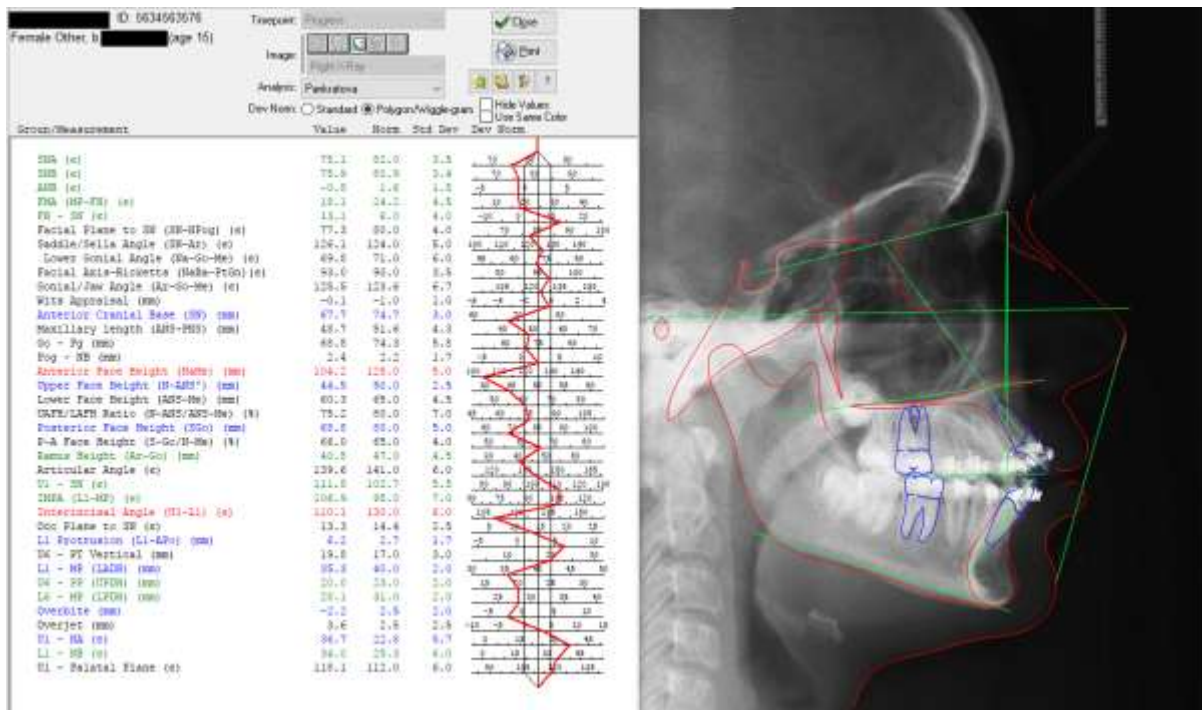
**Fig.3.** Location of the impacted tooth 1.1 of patient O., 13 years old, before orthodontic treatment (angle of inclination of tooth is 30 °)



**Fig.4.** Location of the impacted tooth 1.1 of patient O., 13 years old, in three projections before orthodontic treatment (3rd level of the tooth 1.1 location)

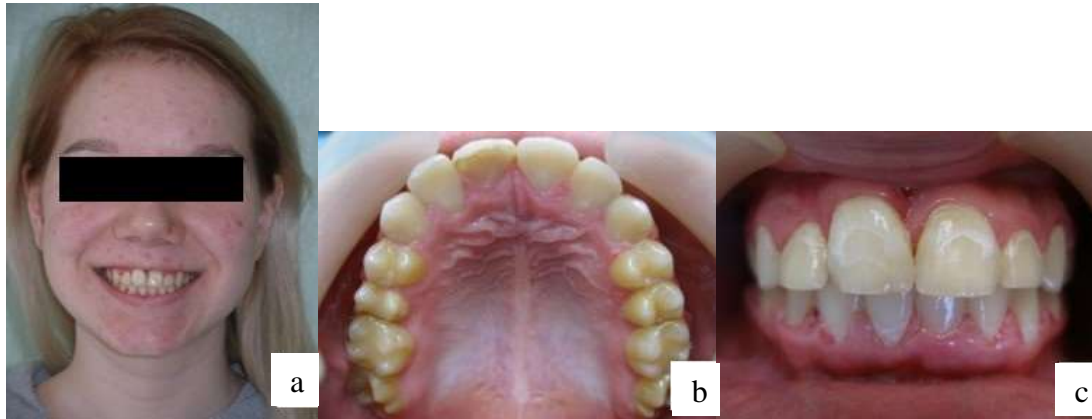


**Fig.5. Determination of angles of the impacted tooth 1.1 inclination:** in the coronary plane - 56.33 °, in the sagittal plane - 129.88 °, in the axial plane - 57.93 °.

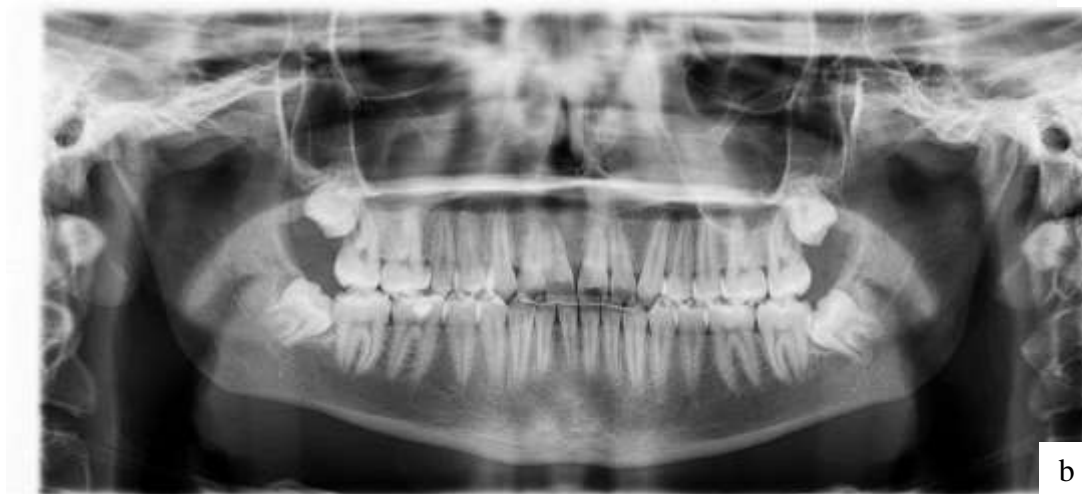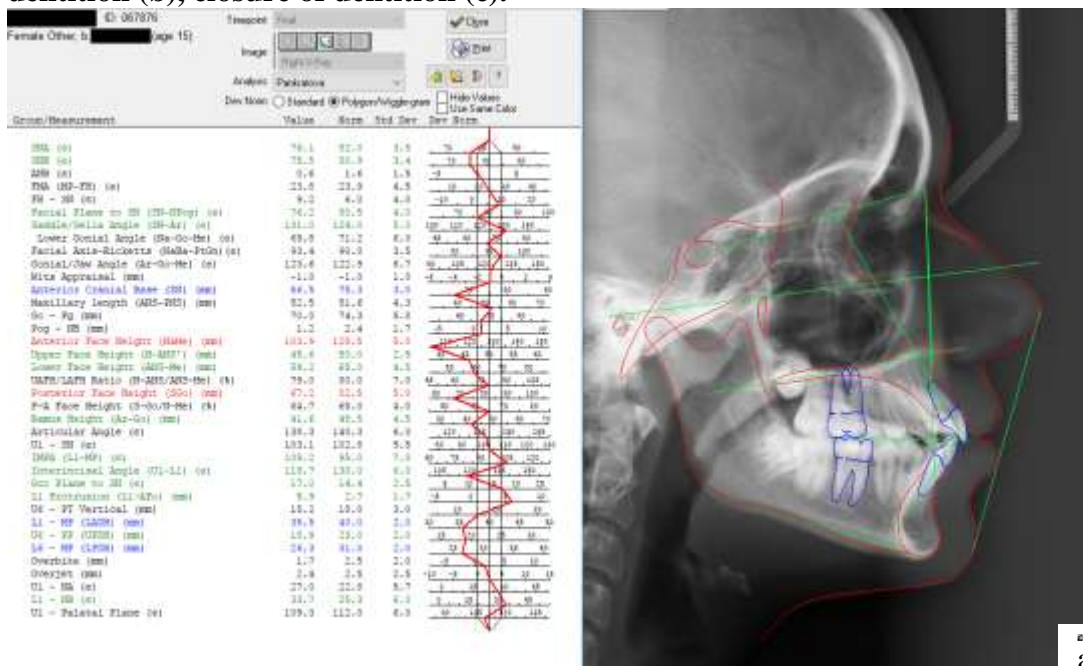


**Fig.6. Cephalometric x-ray image of head in lateral projection of the patient O., 15 years old with analysis using Dolphin Imaging software (USA) at the stage of orthodontic treatment.**





**Fig.7. Photo of patient O., 15 years after orthodontic treatment (patient's face (a), upper dentition (b), closure of dentition (c).**



**Fig.8. Cephalometric x-ray image of head in lateral projection of the patient O., 15 years old with analysis using Dolphin Imaging software (USA) after orthodontic treatment – a; location of the impacted tooth 1.1 after orthodontic treatment – b.**