

12-3-2019

COMPARATIVE ANALYZES OF ICG-VA, DIVA, FLOW 800 IMAGING IN CEREBROVASCULAR SURGERY

Kh. A. Khasanov

Tashkent Medical Academy, Tashkent, Uzbekistan; Fellow in Cerebrovascular surgery, Fujita Health University Banbuntane Hotokukai Hospital, Nagoya, Japan., xasanovneuro@gmail.com

G. A. Alikhodjayeva

Republican Specialized Scientific Practical Medical Center of Neurosurgery, Tashkent, Uzbekistan.

A. Sayah

Fujita Health University Banbuntane Hotokukai Hospital, Nagoya, Japan.

Y. Yamada

Fujita Health University Banbuntane Hotokukai Hospital, Nagoya, Japan., yasuyamada83@yahoo.co.jp

Follow this and additional works at: <https://uzjournals.edu.uz/tma>

Recommended Citation

Khasanov, Kh. A.; Alikhodjayeva, G. A.; Sayah, A.; and Yamada, Y. (2019) "COMPARATIVE ANALYZES OF ICG-VA, DIVA, FLOW 800 IMAGING IN CEREBROVASCULAR SURGERY," *Central Asian Journal of Medicine*: Vol. 2019 : Iss. 4 , Article 3.

Available at: <https://uzjournals.edu.uz/tma/vol2019/iss4/3>

This Article is brought to you for free and open access by 2030 Uzbekistan Research Online. It has been accepted for inclusion in Central Asian Journal of Medicine by an authorized editor of 2030 Uzbekistan Research Online. For more information, please contact sh.erkinov@edu.uz.

COMPARATIVE ANALYZES OF ICG-VA, DIVA, FLOW 800 IMAGING IN CEREBROVASCULAR SURGERY

Kh. A. Khasanov¹, G. A. Alikhodjayeva², I. E. Khujanazarov², A. Sayah³, Y. Yamada⁴, T. Kawase⁵, Y. Kato⁶

1 MD, Department of Traumatology, orthopedics, neurosurgery and military-field surgery, Tashkent Medical Academy, Tashkent, Uzbekistan; Fellow in Cerebrovascular surgery, Fujita Health University Banbuntane Hotokukai Hospital, Nagoya, Japan. 454-0012 (*-corresponding author email: xasanovneuro@gmail.com)

2 Republican Specialized Scientific Practical Medical Center of Neurosurgery, Tashkent, Uzbekistan.

3 MD, Fellow in Cerebrovascular surgery, Fujita Health University Banbuntane Hotokukai Hospital, Nagoya, Japan.

4 MD, PhD, Asst. Professor Department of Neurosurgery, Fujita Health University Banbuntane Hotokukai Hospital, Nagoya, Japan. Email: yasuyamada83@yahoo.co.jp

5 MD, PhD, Asso. Professor Department of Neurosurgery, Fujita Health University Banbuntane Hotokukai Hospital, Nagoya, Japan. email: kawasemi@hm8.aitai.ne.jp

6 MD, PhD, Professor and Chairman of the Department of Neurosurgery, Fujita Health University Banbuntane Hotokukai Hospital, Nagoya, Japan. email: kyoko@fujita-hu.ac.jp

ACA – anterior cerebral artery
Acom – anterior communicating artery
AG – angiography
AVM- arteriovenous malformation
CCA – common carotid artery
CT – computed tomography
DAVF - dural arteriovenous fistula
DIVA – dual-image videoangiography

DSA - digital subtraction angiography
ICA – internal carotid artery
ICG-VA – indocyanine green videoangiography
MCA – middle cerebral artery
MRI – magnetic resonance imaging
PICA – posterior inferior cerebellar artery
STA – superficial temporal artery

ABSTRACT

It is the most important to visualize cerebral vessels along with its surrounding structures during cerebrovascular surgery and it can be easier with real-time angiographic imaging. There are different kinds of indocyanine green dye based videoangiography are commonly used in cerebrovascular surgery.

The objective. Comparative analyzing of ICG-AG, DIVA and Flow 800 color mapping in cerebrovascular surgery.

Materials and methods. Real time surgery assessment of vascular and surrounding structures in 29 cerebral aneurysms clipping, one STA-MCA bypass and 2 carotid artery endarterectomy had been performed using ICG-VA, DIVA, flow 800 color mapping from August to October 2019.

Result. In 23 cases in cerebral aneurysms clipping ICG-VA could not clearly visualize perforators compared to its' better visualization by DIVA. In 3 cases, occlusion of perforators were assessed by DIVA after clip application which was solved by reapplication of surgical clips. In one STA-MCA bypass surgery, patency and sequences of blood inflow to cortical branches of MCA (M4) from recently anastomosed STA branches were assessed with ICG-VA, DIVA and Flow 800 color mapping. Visualization of the lack of blood flow and fluttering atherosclerotic plaques in carotid endarterectomy was observed by ICG-VA, DIVA, flow 800 mapping.

Conclusion. In real time cerebrovascular surgery, ICG-VA, DIVA, and Flow 800 color mapping can be effective tool to better visualization of vascular and surrounding structures. Benefits of flow 800 color mapping outweighs the advantages of both ICG-VA and DIVA. However, DIVA is also better than ICG-VA to visualize.

Key words: dual-image videoangiography, ICG, flow 800. STA-MCA bypass, intraoperative angiography, carotid endarterectomy.

INTRODUCTION

During microvascular procedures, it is crucial to be aware of vascular flow visualization in surgical field. Surgical microscopes equipped with better visualization system make any challenging cerebrovascular intervention possible and effective. Real time surgery ICG dye based angiography is used to observe vascular circulation in superficial and deep spaces, better analyzes microsurgical anatomy of arteriovenous malformations (AVM), dural arteriovenous fistula (dAVF), aneurysms and STA-MCA bypass. In present time, ICG-VA and dual-image videoangiography (DIVA) are mostly used in vascular surgery. In addition to this, during ICG Videoangiography Kamada et al. used original NL camera and the new NIR system to detect anatomical and fluorescence signals during operation, the new NIR system allowed us to observe ICG fluorescence and anatomical structures without image fusion or time-delay. In fact, dual image video angiography provides significant visualization of operative field and vascular circulation simultaneously via ICG-AG, and a novel laser light equipment of surgical microscopes increases effectiveness of dual-image videoangiography while with ICG-VA's monochrome images it is difficult to observe surrounding structures [1,2,3]. Moreover, in case of complex aneurysm that requires multiple clips application small perforators are not visible during ICG-AG. "Flow 800" color mapping a new tool to visualize vascular structures better using different colors which are helpful to distinguish both arterial and venous circulation as well as surrounding structures [4,5]. Abovementioned intraoperative indocyanine based angiographic visualization of vascular structures does not replace a cerebral angiogram which has been known as a gold standard for vascular assessment since it can visualize only vascular structure directly within the field of view of microscope and lacks quantitative interpretation [6]. However, in present time it remains as an effective tool in real time surgery to simultaneously visualise vascular structures.

THE OBJECTIVE OF STUDY

Comparative analyzing of three different types of angiography such as ICG-AG, DIVA and Flow 800 color mapping in cerebrovascular surgery.

MATERIALS AND METHODS

In Fujita Health University Banbuntane Hotokukai Hospital 29 cerebral aneurysms, one STA-MCA bypass and 2 carotid artery endarterectomy cases underwent surgical treatment from August to October 2019. During surgery in all cases ICG-VA, DIVA and in some selected cases plus those visualization, flow 800 color mapping were used before and after main procedures namely, clipping, bypass, endarterectomy. In addition to preoperative CT, MRI, DSA, three-dimensional examination (3D-CTA) was also used pre and postoperatively.

Intraoperative videoangiography and color mapping. Intraoperative ICG-VA, DIVA in all cases and Flow 800 color mapping in some selected cases was performed. The near-infrared color camera MNIRC-200K (Mizuho, JAPAN) equipped surgical microscope OPMI PENTERO Flow 800 equipped with special censor unit and optical filter caused to see visible light and NIR fluorescence emission light to 400-700 nm and 800-900 nm respectively and simultaneously and recently brought hybrid microscope ZEISS KINEVO 900 (Both by Carl Zeiss Meditec, Jena, Germany) were used to visualize surgical field' fluorescent area and to perform surgical procedures. To visualize vascular structures on color map of flow 800 images, hybrid microscope KINEVO 900 was used in selected cases. As reported by some authors², on the color map, red represents the initial blood inflow and the other colors gradients show the subsequent sequences of flow with identification of feeding arteries, en passage vessels, draining veins, as well as normal cortical arteries and veins. During ICG-AG, DIVA visualization, ICG 0.3 mg/kg body weight systemically injected and monitored on single screen.

RESULTS

Of all 29 cerebral aneurysm cases, 12 were male and 17 were female (male to female ratio – 1:1,4). The most commonly aneurysm located in internal carotid artery (IC aneurysm)- 51,7%, following 20,7%, 13,8%, 10,3% and 3,4% in anterior communicating, posterior inferior cerebellar artery, middle cerebral artery and in anterior cerebral artery respectively. Occurrence of aneurysms in anterior circulation dominated posterior circulation with 92,6% and 7,4% respectively. Along with in cerebral aneurysm clipping and carotid artery endarterectomy, in STA-MCA bypass procedures ICG-VA, DIVA, Flow 800 color mapping was performed. There was no adverse effects of ICG dye in all cases and obtained high resolution images enabled to assess the blood flow in the surgical field. Three cases of three different vascular procedures such as aneurysm clipping, STA-MCA bypass and carotid endarterectomy were illustrated using real time surgery angiography by ICG-Ag, DIVA, Flow 800 color mapping given as illustrative cases below. In the cerebral aneurysm cases, along with visualization of perforators by endoscope, ICG-VA and DIVA was performed before and after clipping. In 4 cases ICG-VA could not clearly visualize perforators compared to its' better visualization by DIVA. In 3 cases, occlusion of perforators was assessed by DIVA after clip application which was solved by reapplication of surgical clips. In one STA-MCA bypass surgery, patency and sequences of blood inflow to cortical branches of MCA (M4) from recently anastomosed STA branches were assessed by both ICG-VA, DIVA as well as Flow 800 color mapping were successful. These were also used in two cases of carotid endarterectomy proximal to CCA bifurcation, to visualize the lack of blood flow and fluttering atherosclerotic plaques within level of stenosis before procedure. During surgery, atherosclerotic plaques was dissected and restored blood flow was confirmed by previously used imaging methods.

Illustrative case 1.

70 year old female admitted to department of neurosurgery with history of transient headache. The CT-AG detected unruptured right ACA aneurysm. (Figure 1. A.) and anterior interhemispheric approach was performed to successfully clip right distal part of right distal anterior cerebral artery's aneurysm. After having access to the aneurysm, DIVA was used to visualize anterior cerebral artery aneurysm and optic nerve. Following sufficient dissection of aneurysm from surrounding structure, aneurysm was clipped, post clip DIVA illustrated a bit flow and uncompleted occlusion of aneurysm then second clip application is done at the level of uncompleted occlusion. Patency of artery and complete decompression of optica nerve, total occlusion of aneurysm were checked using DIVA again (figure-1-B,C,D,E,F,G.). Postoperative period was without complication.

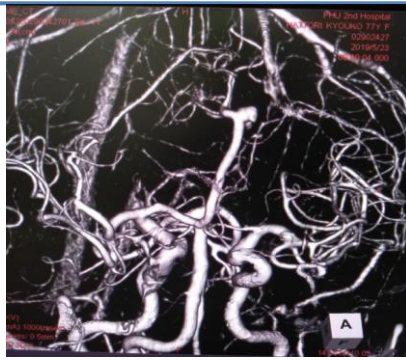

Figure 1. CTA image illustrates anterior cerebral artery A2 distal aneurysm.

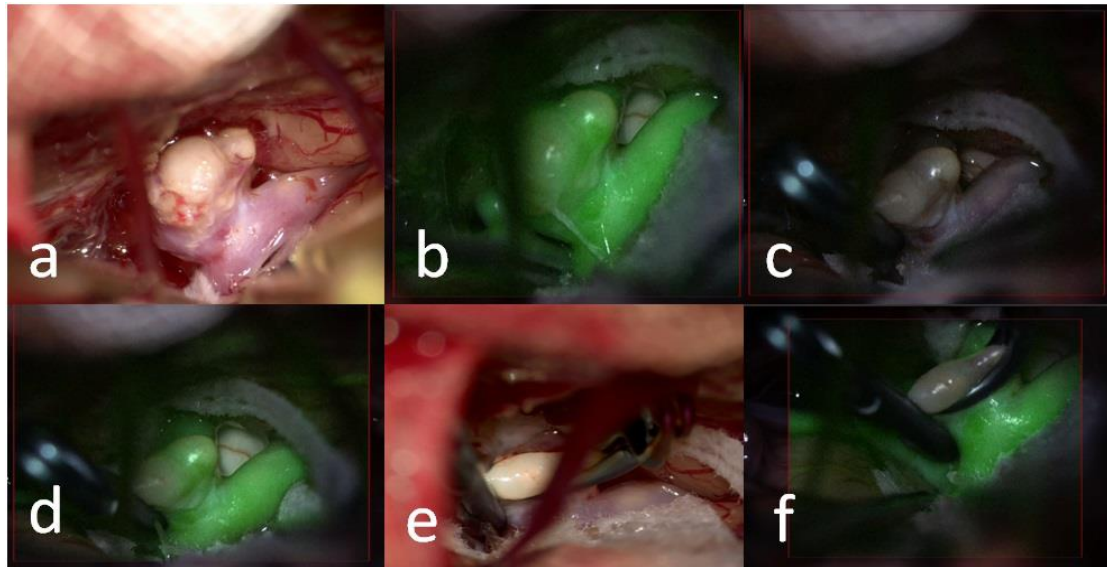


Figure 2. shows CT angiography and real time surgery image illustrating anterior cerebral artery aneurysm (a), real time dual image videoangiography of ACA aneurysm (b) initial clip application (c), intraoperative DIVA illustrating uncompleted occlusion of the aneurysm, (d), second clip done (e), Post clip DIVA illustrating complete occlusion of aneurysm with little residual aneurysm neck (f).

Illustrative case 2

64-year-old man with right ICA stenosis at its cervical segment just close to foramen lacerum confirmed on CTA-AG admitted to our hospital. Right STA-MCA (M4) bypass was performed and real time surgery ICG-AG, DIVA and flow 800 mapping was used to visualize vascular and surrounding structures (figure 3 and 4). Real time imaging studies confirmed significant blood flow through anastomosis during bypass procedure which was carried out step by step with both frontal and parietal branches of STA.

Figure 3. Intraoperative visualization of STA connected to cortical (M4) segments of MCA with its temporal branch and ICG-AG, DIVA visualization and Flow 800 color map confirming effective complete bypass (a,b,c,d). Temporal and frontal branches of STA connected MCA -M4 (e), and their ICG-VA (f), DIVA (g) and with flow 800 color mapping visualization(k).

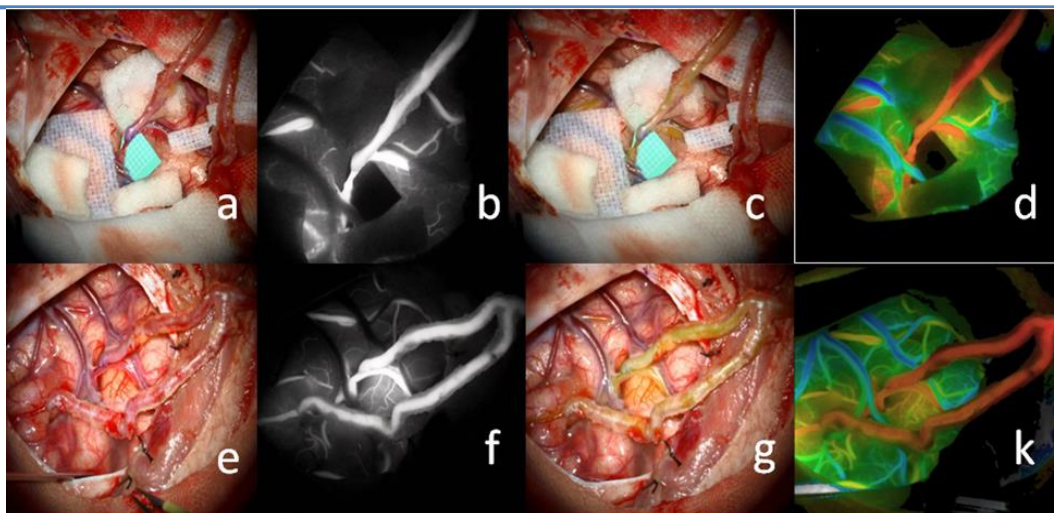


Figure 3. Post operative CTA 3D image visualizing bypass.

Illustrative case 3.

74 year old man with history of transient headache and weakness in right extremities admitted to the Fujita Health University Bantane Hospital. Preoperative CT-AG detected left carotid artery (CA) stenosis. Carotid endarterectomy was performed using intraoperative angiography to visualize vessel patency and blood flow before and after endarterectomy. ICG-AG and DIVA before endarterectomy confirmed narrowing CCA bifurcation and post endarterectomy ICG-AG, DIVA and high flow 800 visualization illustrated significant improvement in blood flow after atherosclerotic plaque removal (figure 4).

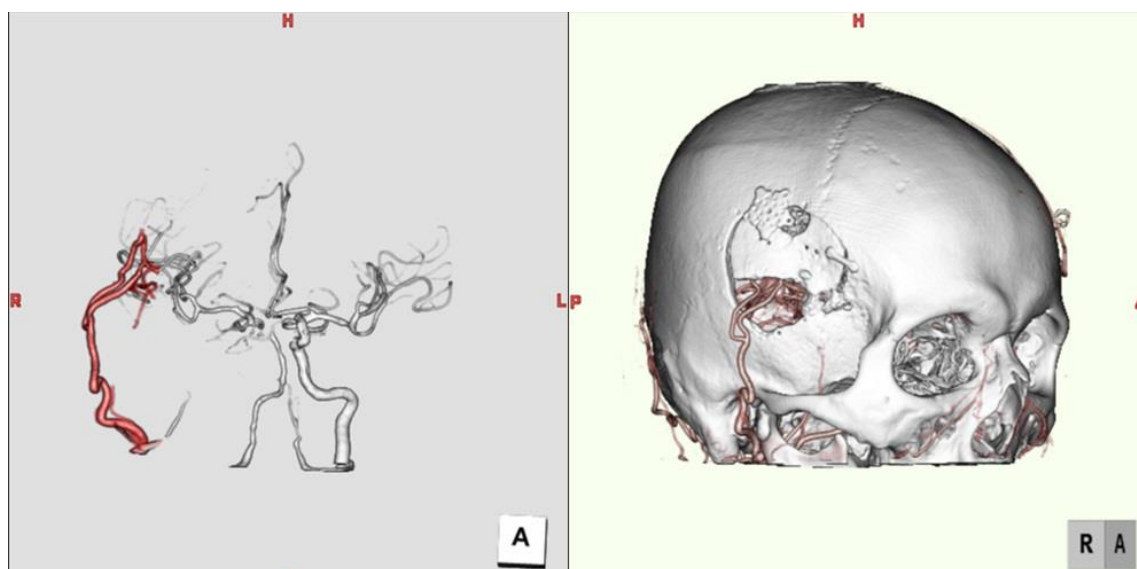
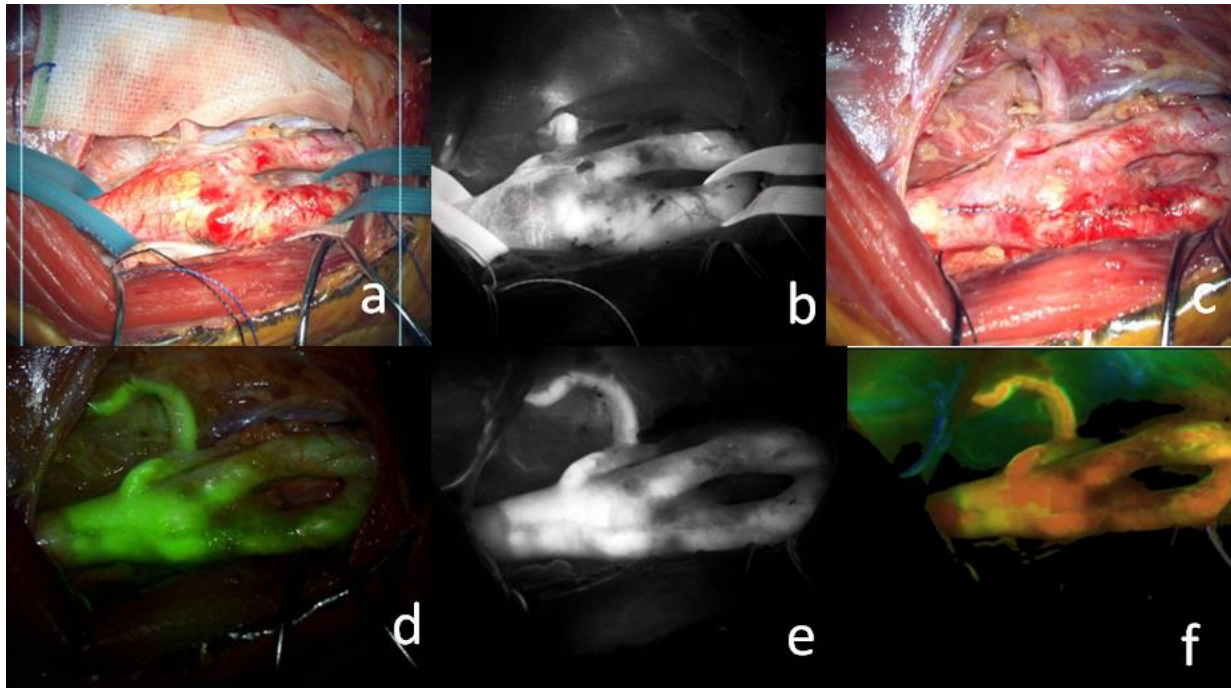


Figure 4. shows real time surgery visualization of stenotic Carotid bifurcation with visible atherosclerotic plaques (a), ICG videoangiography confirms atherosclerotic plaque as darkness view in white background, longitudinal sutures after endarterectomy (c), with DIVA (d), ICG-VA (e) and Flow 800 color map (f) confirmation of plaque removal.



DISCUSSION

ICG was introduced to the world practice in the Second World War as a dye in photography and tested in 1957 at the Mayo clinic for use in human medicine. First ICG usage focused on diagnostic procedure in hepatic diseases and later in cardiology, and recently in cancer treatment^{3, 4}. In mid 1968, first successful ICG-AG on brain was done by Earl and Kogure at the University of Miami Medical School making an experiment with owl monkeys. Later they made first experiment on a volunteer a patient but result was not acceptable⁶. In 2003, Alberto et al. reported its usefulness during neurovascular procedure. ICG-VA can visualize a clear and intraoperative vascular image during microsurgical procedures⁷ such as incomplete clipping during surgical procedures in patients with unruptured aneurysms can also be assessed with ICG-VA⁸. Furthermore, there is a report of indocyanine green usage for indicating the position of internal carotid artery during endoscopic endonasal transphenoidal surgery⁹. However, it cannot visualize surrounding structures other than NIR fluorescence white colored image of vessels in dark background field. This problem had been solved by Martirosyan and et al. realizing a fluorescence angiography with augmented microscopy enhancement (FAAME) on animal studies and proved that it enables green-fluorescent NIR images to be superimposed to white light anatomical field and this technique helped to identify small vessels covered with a thin connective¹⁰. Sato et al reported similar case developing dual image videoangiography, a novel tool to observe surrounding structures¹¹. Since the creation of DIVA it is being used worldwide. This creation made the most challenging neurovascular procedures possible and effective because it gives vessel colored with green during altered dynamic of blood flow after ICG dye injection. DIVA has some benefits compared to ICG-AG, First of all, it is very helpful to visualize surrounding structure; nerve, clips and deep located perforators and parent vessel while ICG-AG do not. However, in ruptured micro-AVMs ICG-VA usage in confirming AV shunts, AVMs with superficial drainage is reported by many authors as safe and effective¹² but both ICG-VA and DIVA provides only anatomical data without any information about the physiology and dynamics of blood flow. However, Flow 800 that can produce intensity diagrams, color mapping is a new image analysis software package can distinguish physical properties of the flow in vessels and demonstrates semi quantitative data was developed to tackle this problem¹⁴. It was reported to be useful tool to visualize feeding arteries of Spetzler-Martin

Grade IV right parietal aneurysm. The subsequent intensity diagram and color map of flow 800 facilitated the distinction of AVM vessels, namely, feeding arteries, draining veins, arterialized veins from other normal vessels, such as arteries *en passage*¹⁵. Apart from intracranial vascular pathologies, extracranial artery diseases also increases risk of cerebrovascular pathologies related disorders and carotid artery stenosis is well known to be one of the most common causes of stroke. ICG-VA was also reported to detect fluttering atheroma¹⁶. In our study, both ICG-VA and DIVA as well as Flow 800 color mapping used to visualize surrounding structures within surgical field of microscope was effective to perform surgical procedures, and distinction of arterial-venous circulation was also effective in bypass.

CONCLUSION

Intraoperative angiography is effective methods to evaluate result of vascular surgery, ICG-AG, DIVA are widely used in neurovascular practice throughout the world. Due to its' effectiveness and high resolution image DIVA is more advantageous than ICG-AG, it gives better vessels' visualization among other surrounding structures. However, Flow 800 color mapping outweighs benefits of both ICG-AG and DIVA due to its high quality visualization of anatomical structure in operative field with better differentiated vessel observation during cerebrovascular surgery showing the occlusion of aneurysm and perforator arteries in deep space and better discrepancies of vascular structures and normal brain tissue.

REFERENCES

1. Riki Tanaka, Anton Shatokhin, Ilya Senko, Ishu Bishnoi, Treepob Sae-Ngow, Yasuhiro Yamada, Daisuke Suyama, Tsukasa Kawase, Yoko Kato, Ahmed Ansari. Real-time patency verification during clipping aneurysm and STA-MCA by-pass with dual-image videoangiography. *Romanian Neurosurgery* (2018) XXXII 1: 35 - 39
2. Kushal J. Shah and Aaron A. Cohen-Gadol. The Application of FLOW 800 ICG Videoangiography Color Maps for Neurovascular Surgery and Intraoperative Decision Making. *World Neurosurg.* 2019 Feb;122:e186-e197. doi: 10.1016/j.wneu.2018.09.195. Epub 2018 Oct 5.
3. Jarmo T. Alander, Ilkka Kaartinen, Aki Laakso, Tommi Patila, Thomas Spillmann, Valery V. Tuchin, Maarit Venermo, and Petri Valisuo. A Review of Indocyanine Green Fluorescent Imaging in Surgery. Hindawi Publishing Corporation International Journal of Biomedical Imaging Volume 2012, Article ID 940585, 26 pages. doi:10.1155/2012/940585
4. Gal Shafirstein, Wolfgang Bäuml, Leah J Hennings, Eric R Siegel, Ran Friedman, Mauricio A Moreno, Jessica Webber, Cassie Jackson, and Robert J Griffin. Indocyanine Green Enhanced Near Infrared Laser Treatment of Murine Mammary Carcinoma. *Int J Cancer.* 2012 March 1; 130(5): 1208–1215. doi:10.1002/ijc.26126.
5. Thind H, Hardesty DA, Zabramski JM, Spetzler RF, Nakaji P. The role of microscope-integrated near-infrared indocyanine green videoangiography in the surgical treatment of intracranial dural arteriovenous fistulas. *J Neurosurg.* 2015 Apr;122(4):876-82. doi: 10.3171/2014.11.JNS14947. Epub 2015 Jan 2
6. Earl A. Choromokos, Nobel J. David, "The beginning of Indocyanine Green Angiography" – *Journal of Ophthalmic Photography* Vol. 16, No 2, October 1994
7. Feletti A, Wang X, Tanaka R, Yamada Y, Suyama D, Kawase T, Sano H, Kato Y, Dual-image videoangiography during intracranial microvascular surgery, *World Neurosurgery* (2017), doi: 10.1016/j.wneu.2016.12.070.
8. Imizu S, Kato Y, Sangli A, Oguri D, Sano H. Assessment of incomplete clipping of aneurysms intraoperatively by a near-infrared indocyanine green-video angiography (Niicg-Va) integrated microscope. *Minim Invasive Neurosurg* 2008;51:199-203.
9. Kenichi Oyama, Shigeyuki Tahara, Toshio Hirohata, Yudo Ishii, Daniel M Prevedello, Ricardo L Carrau, Sebastien Froelich, Akira Teramoto, Akio Morita, and Akira Matsuno.

- Surgical Anatomy for the Endoscopic Endonasal Approach to the Ventrolateral Skull Base. *Neurol Med Chir (Tokyo)* 57, 534–541, 2017. doi: 10.2176/nmc.ra.2017-0039.
10. Nikolay L. Martirosyan, Jesse Skoch, Jeffrey R. Watson, G. Michael Lemole Jr, Marek Romanowski, Rein Anton. Integration of Indocyanine Green Videoangiography With Operative Microscope: Augmented Reality for Interactive Assessment of Vascular Structures and Blood Flow. *Operative Neurosurgery* 11:252–258, 2015 DOI: 10.1227/NEU.0000000000000681.
 11. [Sato T](#), [Bakhit M](#), [Suzuki K](#), [Sakuma J](#), [Fujii M](#), [Murakami Y](#), [Ito Y](#), [Sure U](#), [Saito K](#). A Novel Intraoperative Laser Light Imaging System to Simultaneously Visualize Visible Light and Near-Infrared Fluorescence for Indocyanine Green Videoangiography. *Cerebrovasc Dis Extra* 2018;8:96–100.
 12. Oya S, Nejo T, Fujisawa N, Tsuchiya T, Indo M, Nakamura T, *et al*. Usefulness of repetitive intraoperative indocyanine green-based videoangiography to confirm complete obliteration of micro-arteriovenous malformations. *Surg Neurol Int* 2015;6:85.
 13. John E. Wanebo, Sepideh Amin-Hanjani, Cynthia Boyd, Terry Peery. Assessing Success after Cerebral Revascularization for Ischemia. *Skull Base*. 2005 Aug; 15(3): 215–227.
 14. Kato Y., Sakarunchai I., Nouri M. (2019) FLOW 800 for Vascular Surgery. In: July J., Wahjoepramono E. (eds) *Neurovascular Surgery*. Springer, Singapore.
 15. Chen SF, Kato Y, Oda J, Kumar A, Watabe T, Imizu S, Oguri D, Sano H, Hirose Y. The application of intraoperative near-infrared indocyanine green videoangiography and analysis of fluorescence intensity in cerebrovascular surgery. *Surg Neurol Int* 2011;2:42
 16. Chang-Hyun Lee, Young Sub Jung, Hee-Jin Yang, Young-Je Son, Sang Hyung Lee. An innovative method for detecting surgical errors using indocyanine green angiography during carotid endarterectomy: a preliminary investigation. *Acta Neurochir (2012)* 154:67–73 DOI 10.1007/s00701-011-1212-1
 17. Kyousuke Kamada, Christoph Guger, Fumiya Takeuchi. Multispectrum Indocyanine Green Videography for Visualizing Brain Vascular Pathology. *World Neurosurg.* (2019) 132:e545-e553. <https://doi.org/10.1016/j.wneu.2019.08.078>.